

Successful Management of Thyroid Storm with Continuous Renal Replacement Therapy without Plasma Exchange

Calvin Kurnia Mulyadi¹, Elizabeth Yasmine Wardoyo¹, Anggraini Permata Sari¹, Aryan Yohanes¹, Sarwono,¹ Fidkya Allisha,¹ Marina Epriliawati², M. Ikhsan Mokoagow²

¹Division of Nephrology and Hypertension, Department of Internal Medicine, Fatmawati Central General Hospital, Jakarta, Indonesia

²Division of Endocrine Diabetes and Metabolic, Department of Internal Medicine, Fatmawati Central General Hospital, Jakarta, Indonesia

ARTICLE INFO	ABSTRACT
<p><i>Article history:</i> Received: June 6, 2025 Accepted: August 21, 2025 Published Online: August 24, 2025</p>	<p>Thyroid storm is a life-threatening endocrine emergency that needs urgent management. Conventional therapies, however, may not always yield a satisfactory outcome. Hereby, we report a case of refractory thyroid storm with hemodynamic and cardiac instability that showed significant improvement following continuous renal replacement therapy (CRRT) instead of therapeutic apheresis. A 46-year-old woman presented with severe thyrotoxicosis and pneumonia. On admission, she was alert and hemodynamically stable. Examination revealed irregular tachycardia, persistent fever, exophthalmos, diffuse goiter, and bilateral pulmonary rales. Laboratory tests showed primary thyrotoxicosis, leukocytosis, and elevated procalcitonin consistent with sepsis. The Burch-Wartofsky score was 65, confirming thyroid storm. Despite optimal medical therapy, she deteriorated with loss of consciousness and unstable supraventricular tachycardia. Given the poor response, continuous venovenous hemofiltration (CVVH) was initiated for 33 hours, resulting in clinical improvement with reduction in free thyroxine (fT₄), hemodynamic stabilization, and recovery of consciousness. While therapeutic plasma exchange (TPE) is the recommended adjunctive therapy for refractory thyroid storm per the ASFA 2016 guidelines, it is often unavailable in many centers, particularly in low-resource settings. CRRT may serve as an alternative, offering hemodynamic stabilization through mechanisms not yet fully understood. CRRT may be considered a safe and effective alternative treatment for thyroid storm in patients who are refractory to standard medical therapy, and particularly for those presenting with hemodynamic instability.</p> <p>Keywords: Medical-treatment Refractory Thyroid Storm, Continuous Renal Replacement Therapy, Hemodynamic Instability.</p>
<p><i>Corresponding Author:</i> Calvin Kurnia Mulyadi, Division of Nephrology and Hypertension, Department of Internal Medicine, Fatmawati Central General Hospital, Jakarta, Indonesia, calvinkurnia@gmail.com</p>	

Introduction

Thyroid storm is a critical and potentially fatal endocrine emergency. Several precipitating factors can trigger this condition in patients with underlying hyperthyroidism, including infections, myocardial infarction, stroke, heart failure, non-thyroid surgery, poor adherence to antithyroid medications, and pregnancy or labor. The first-line treatment typically involves high-dose antithyroid drugs in combination with

glucocorticoids. These conventional therapies aim to suppress thyroid hormone synthesis and release, as well as mitigate the peripheral effects of excessive hormone levels.

However, in some cases, patients may not respond adequately to standard treatment, resulting in prolonged thyrotoxicosis and an increased risk of cardiovascular complications. According to the 2016 American Thyroid

Cite this as:

Mulyadi CK, Wardoyo EY, Sari AP, et al. Successful Management of Thyroid Storm with Continuous Renal Replacement Therapy without Plasma Exchange. *InaKidney*. 2025;2(2):93-97. doi: 10.32867/inakidney.v2i2.195



Association (ATA) guidelines, therapeutic plasma exchange (TPE) may be considered for patients who fail to respond to conventional therapies. Continuous renal replacement therapy (CRRT), though less commonly reported, may offer benefits by facilitating the clearance of medium-to-large molecules. This case report aims to describe the successful use of CRRT as an alternative to therapeutic plasma exchange in a patient with thyroid storm and hemodynamic instability refractory to standard therapy.

Case Illustration

A 46-year-old woman presented to the emergency department with a one-week history

of fever and productive cough. Her medical history included uncontrolled hypertension. She also reported non-radiating chest pain, palpitations, reduced appetite, and a 15 kg weight loss over two months. Symptoms of chronic hyperthyroidism—frequent bowel movements, hair thinning, tremors, heat intolerance, and anxiety—had recently worsened.

On admission, she was alert. Vital signs were: blood pressure 150/90 mmHg, irregular pulse 150 beats/min, respiratory rate 26 breaths/min, and temperature 38 °C. Examination revealed bilateral pulmonary rales, exophthalmos, and diffuse thyroid enlargement (Fig. 1A, 1C).

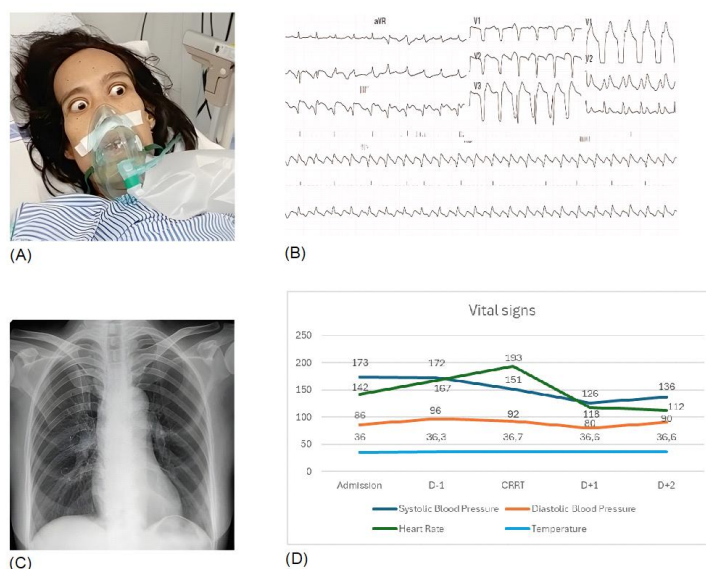


Figure 1. Clinical findings during hospitalization. (A) Exophthalmos, (B) Supraventricular tachycardia on electrocardiogram, (C) Bilateral pulmonary infiltrates, and (D) Trends of vital signs before and after CRRT

Laboratory results before and after continuous renal replacement therapy (CRRT) are shown in Table 1. The Burch-Wartofsky Point Scale (BWPS) score was 65, consistent with thyroid storm. Contributing factors included fever, tachycardia, atrial fibrillation, and signs of heart failure. On the following day, her condition

worsened. Electrocardiography showed progression from atrial fibrillation to supraventricular tachycardia (Fig. 1B). Elevated cardiac troponin I confirmed non-ST elevation myocardial infarction (NSTEMI).

Table 1. Initial and Serial Laboratory Parameters before and after CRRT

Parameters	Before CRRT	After CRRT	Reference Value
Hemoglobin (g/dL)	9.9	8.7	11.5 – 15.5
White Blood Cell [WBC] (/uL)	14,400	12,700	5,000 – 10,000
Platelet count (/uL)	310,000	133,000	150,000 – 440,000
Procalcitonin (ng/dL)	2.25	< 0.07	<0.5: Normal 0.5 – <2: Systemic sepsis 2 – <10: Severe sepsis >=10 ng/mL: Septic shock
Cardiac Troponin I (ng/mL)	5.82	0.07	≤ 0.02
Ureum (g/dL)	27.9	N/A	16,5 – 48,5
Creatinine (g/dL)	0.61	N/A	0,50 – 0,95
Serum TSH	0.01	0.01	0.27 – 4.20
Serum free T4	>7.77	0.76	0.92 – 1.68

She received intravenous digoxin, hydrocortisone (300 mg/day), propylthiouracil (250 mg every six hours), propranolol (40 mg every six hours), and broad-spectrum antibiotics. Lugol’s iodine was not available. Despite therapy, she developed hypotension refractory to vasopressors and inotropes, progressing to shock, decreased consciousness, and respiratory distress.

Continuous venovenous hemofiltration (CVVH) was initiated with a blood flow rate of 150–180 mL/min, post-dilution replacement fluid 1.5 L/hour, pre-dilution 500 mL/hour, and unfractionated heparin 600 U/hour. The session

lasted 33 hours. Antithyroid drugs were continued without dose adjustment.

The patient demonstrated gradual clinical improvement. Heart rate decreased, mean arterial pressure (MAP) was sustained with reduced vasopressor support, and serum thyroid hormone levels declined notably by the third day of CVVH (Fig. 1D and Fig. 2). She was discharged on day 14 with a maintenance regimen of propylthiouracil 300 mg three times daily, propranolol 40 mg twice daily, and anticoagulation therapy for baseline atrial fibrillation.

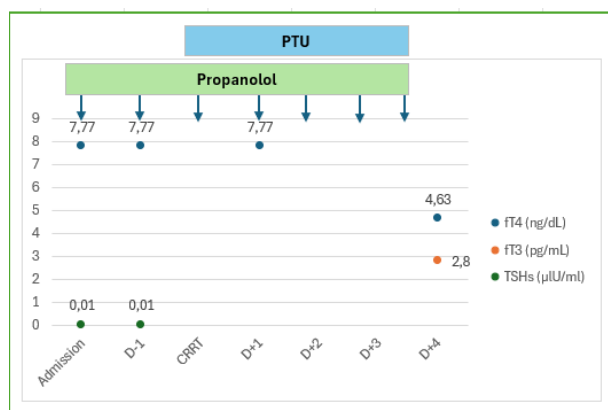


Figure 1. Trends of thyroid hormones before and after CRRT

ft4: free Thyroxine, ft3: free Triiodothyronine, TSHs: sensitive Thyroid Stimulating Hormone, WBC: White Blood Count, PCT: procalcitonin

Discussion

Thyroid storm carries a high mortality rate, ranging from 10% to 75%.¹ In severe cases that do not respond to conventional therapies, alternative treatments such as plasmapheresis and therapeutic plasma exchange (TPE) are often considered. These interventions are capable of removing both free and protein-bound thyroid hormones, as well as circulating autoantibodies.²

According to the 2016 American Thyroid Association (ATA) guidelines, TPE may be considered in patients with thyroid storm refractory to standard therapy or when conventional treatments are contraindicated.³ Similarly, the 2019 American Society for Apheresis (ASFA) guidelines classify TPE as a second-line (Category II) therapy in thyroid storm management, especially when standard treatments are ineffective.^{4,5} Despite these recommendations, the availability of TPE is very limited in many healthcare systems, particularly in resource-limited countries.

In the present case, we successfully utilized continuous renal replacement therapy (CRRT) alone, specifically continuous venovenous hemofiltration (CVVH), to manage a patient with thyroid storm complicated by shock, sepsis, and non-ST elevation myocardial infarction (NSTEMI) who failed to respond adequately to conventional therapy. While TPE is frequently employed in conjunction with CRRT,⁶⁻⁸ This case highlights the potential utility of CRRT as a stand-alone modality in critical circumstances where TPE is unavailable.

A prior report has also described clinical improvement following CRRT without TPE in a similar setting.⁸ Notable benefits included rapid reduction in body temperature, deceleration of heart rate, and improved blood pressure. The mechanisms by which CRRT contributes to such stabilization remain incompletely understood, but several plausible pathways have been proposed:

1. **Thermal modulation:** The use of large volumes of room-temperature dialysate and replacement fluids can induce mild

hypothermia, attenuating the hypermetabolic state of thyrotoxicosis.

2. **Hormone-binding capacity:** Infusion of albumin and plasma components during CRRT may increase the binding of free thyroid hormones, thereby reducing the biologically active fraction.
3. **Cytokine clearance:** CRRT has been shown to facilitate the removal of pro-inflammatory cytokines and other mediators, which may mitigate the systemic inflammatory response and contribute to hemodynamic improvement in critically ill patients.⁸

Unlike intermittent hemodialysis, CRRT provides continuous solute and fluid removal over 24 hours, making it more tolerable for patients with unstable hemodynamics. Although TPE is highly effective—removing up to 80% of circulating T₃ and T₄—its effects are transient, typically lasting only 24–48 hours, and may be associated with rebound thyrotoxicosis if not accompanied by antithyroid medication.^{4,9} Thus, ongoing pharmacologic therapy remains essential regardless of extracorporeal modality.

Limitations of this report include the description of a single case, absence of direct measurements of hormone-binding or cytokine clearance during CRRT, and lack of a head-to-head comparison with TPE. Nevertheless, this case adds to the growing body of evidence suggesting that CRRT may provide meaningful clinical benefit in thyroid storm, particularly in resource-limited settings where TPE is not readily accessible.

Conclusion

Early recognition and aggressive management of thyroid storm are essential to reduce its high mortality. While the 2016 ATA and 2019 ASFA guidelines recommend TPE as a second-line therapy in refractory cases, access remains limited in many healthcare settings. This case highlights that CRRT, particularly in patients with shock, sepsis, and hemodynamic instability,

may provide meaningful clinical benefit even in the absence of TPE. Despite the limitations of a single case report, our findings support consideration of CRRT as a feasible therapeutic option for critically ill patients with thyroid storm when TPE is unavailable.

Declarations

Competing interests

The authors declare no conflict of interest.

Acknowledgments

We gratefully acknowledge the medical and non-medical staffs in emergency unit, intensive care unit, hemodialysis unit, and also division of nephrology and hypertension RSUP Fatmawati who had been involved in the care of the patient presented in this case report.

References

1. Groot LJ De, Bartalena L, Feingold KR. Thyroid Storm [Internet]. 2022. Available from: <https://www.ncbi.nlm.nih.gov/books/NBK278927/>
2. Kahaly GJ, Bartalena L, Hegedüs L, Leenhardt L, Poppe K, Pearce SH. European thyroid association guideline for the management of graves' hyperthyroidism. *Eur Thyroid J*. 2018;7(4):167–86. doi:10.1159/000490384
3. Ross DS, Burch HB, Cooper DS, Greenlee MC, Laurberg P, Maia AL. American Thyroid Association Guidelines for Diagnosis and Management of Hyperthyroidism and Other Causes of Thyrotoxicosis. *Thyroid*. 2016;26(10):1343–421. doi:10.1089/thy.2016.0229
4. Tan AWK, Lim BSP, Hoe JKM, Hoi WH, Leow MKS. Therapeutic plasma exchange for control of thyroid storm. *J Clin Apher* [Internet] [Internet]. 2021;36(1):189–95. Available from: <https://pubmed.ncbi.nlm.nih.gov/32823374/> doi:10.1002/jca.21832
5. Padmanabhan A, Connelly-Smith L, Aqai N, Balogun RA, Klingel R, Meyer E. Guidelines on the Use of Therapeutic Apheresis in Clinical Practice - Evidence-Based Approach from the Writing Committee of the American Society for Apheresis: The Eighth Special Issue. *J Clin Apher*. 2019;34(3):171–354. doi:10.1002/jca.21705
6. Lim SL, Wang K, Lui PL, Ramanathan K, Yang SP. Crash Landing of Thyroid Storm: A Case Report and Review of the Role of Extra-Corporeal Systems. *Front Endocrinol*. 2021;12:725559. doi:10.3389/fendo.2021.725559
7. Ba JH, Wu BQ, Wang YH, Shi YF. Therapeutic plasma exchange and continuous renal replacement therapy for severe hyperthyroidism and multi-organ failure: A case report. *World J Clin Cases*. 2019;7(4):500–7. doi:10.12998/wjcc.v7.i4.500
8. Park HS, Kwon SK, Kim YN. Successful treatment of thyroid storm presenting as recurrent cardiac arrest and subsequent multiorgan failure by continuous renal replacement therapy. *Endocrinol Diabetes Metab Case Rep*. 2017;2017:16–0115. doi:10.1530/edm-16-0115
9. Muller C, Perrin P, Faller B, Richter S, Chantrel F. Role of plasma exchange in the thyroid storm. *Ther Apher Dial* [Internet]. 2011;15(6):522–31. Available from: <https://pubmed.ncbi.nlm.nih.gov/22107688/> doi:10.1111/j.1744-9987.2011.01003.x